

**DEGENERATIVE INSTABILITY OF THE  
LUMBAR SPINE**

***SOFT  
STABILIZATION WITH INTER-  
VERTEBRAL  
LIGAMENTOPLASTY***

**P.L. PEYROU, D. GASTAMBIDE PARIS**

## INTRODUCTION

Chronic lumbalgia: very important morbidity

Spine physiotherapy and ergonomics improve patient's conditions. ■

arthrodesis: you can't come back

consequences for the above and subjacent levels.

In between medical treatments, arthrodesis or discal prosthesis, comes inter vertebral ligamentoplasty.

- ✓ *easy technique,*
- ✓ *conservative* ■
- ✓ *efficient stabilization* in flexion-extension and rotation.

# PHYSIOPATHOLOGICAL REMINDER

the pure rotation movements ( $N \leq 2$  or 3 degrees) transformation into geometric movements of torsion.

leading automatically to flexion or extension ■

- pure inter-vertebral rotation pathological movements : lumbar degeneration
- dehydration and irreversible loss of discal elasticity with time
- reduce disc range of movement
- transform the harmonious inter-vertebral movements into hiccough on the posterior vertebral ligament and joints.
- disk collapse reduce the physiological lordosis

The whole of this involution, disk, capsule, posterior joints, and inter-vertebral ligament reduces the vertebral pre-constraint system to a kind of potential instability.



This instability can be revealed in 2 stages:

**1st Stage:**

decoaptation accidents. consequences of a rotative subluxation between the vertebrae and can be revealed by the “Twist Test” with the scanner.

**2nd Stage:**

by an anatomical stenosis, when all discal modifications (ligaments and joints) decrease the periradicular space. Any abnormal movement leads then to a mechanical compression of the root.

Aim of the inter-vertebral ligamentoplasty :  
restrict the mobility of the unstable segment.

The various biomechanical studies, on the inter-vertebral ligamentoplasty (Senegas-Lavaste) prove the efficiency of this procedure, which decreases by 80% the normal articular amplitudes.

# **INSTABILITY DEFINITION AND MEASURE**

In 1985, POPE and PANJABI have outlined a definition for the lumbar instability as “a loss of segmental rigidity, where the application of strength leads to a wider moving than in a normal structure”.

Originality, instability can have in the background some severe lumbago, sharp pains occurring during a rotating movement or even a turn back, or also a simple sneeze, or walking on a hard ground. ■

Radiologically, usual signs of discal involution are found combined with an evaluated arthrosis of the rachis.

However, radiological signs can sometimes be less obvious, especially in the initial stage.

Measure the inter-vertebral instability and the translation, on dynamic pictures.

The dynamic scanner in torsion sometimes reveals an articular decoaptation (interfacettal gap).



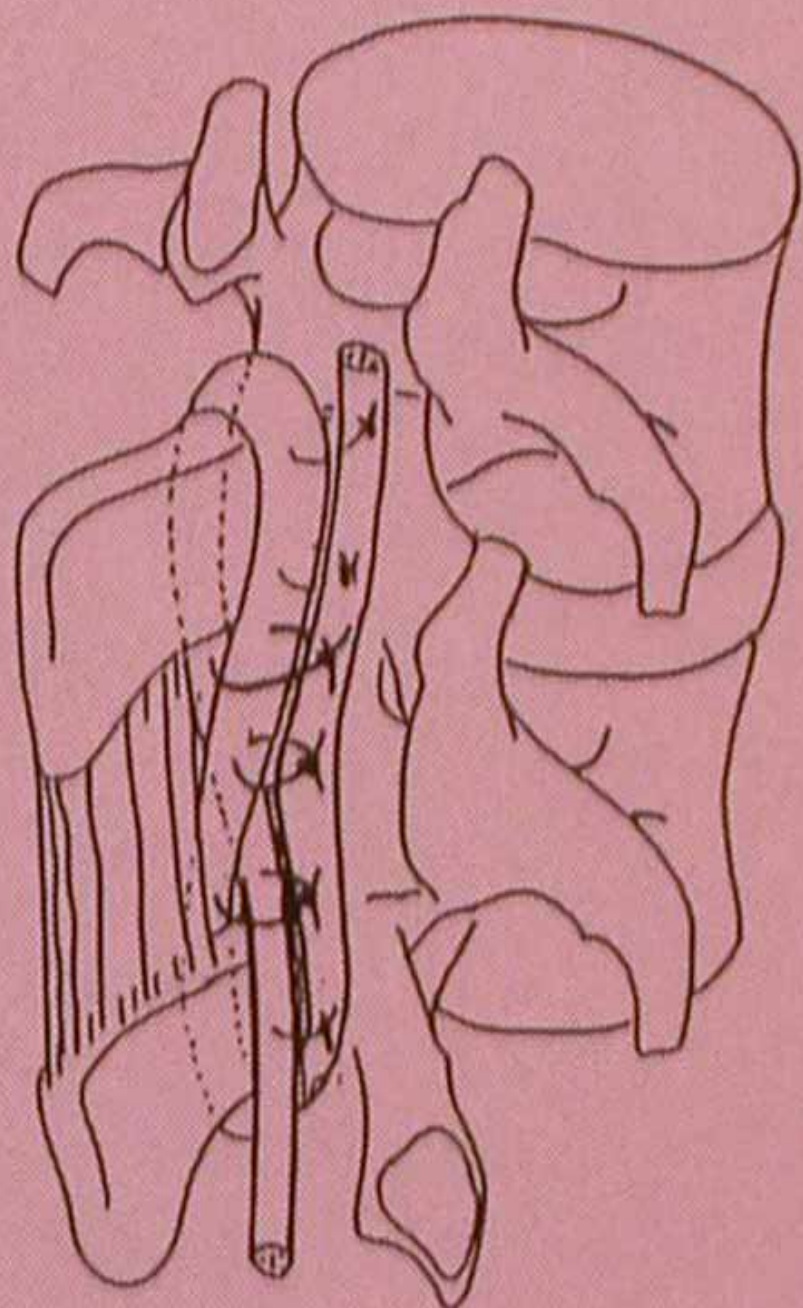
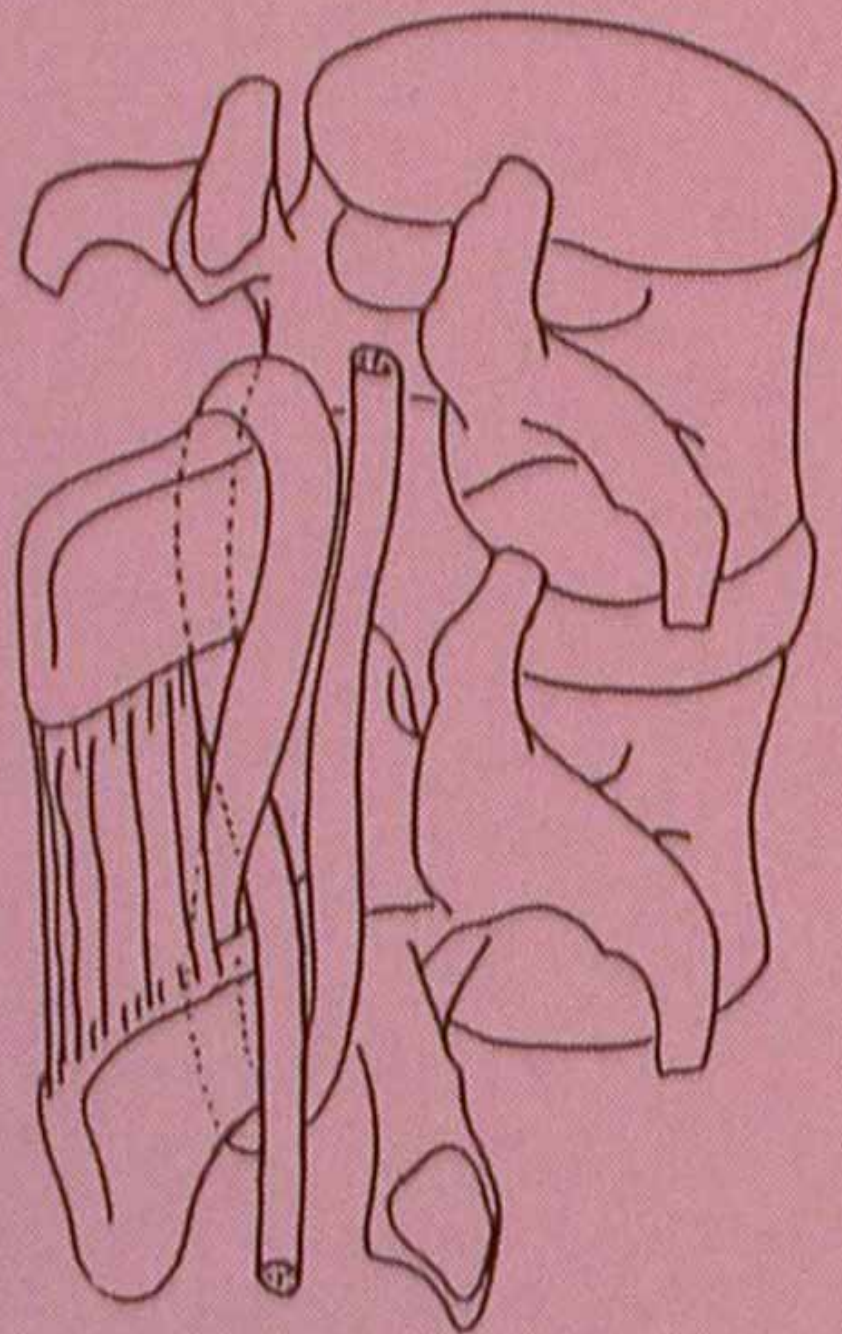
In these cases of instability, the RMI can reveal:

In the first stage:

A fatty degeneration on each side of the rear joints.

In the second stage:

A clear sub chondral band revealing an inflammation. ■



# THE LVR LIGAMENT

40 cm cord, made of a polyethylene braid. Its extremities are prolonged with a traction thread and a needle.

- ✓ no pedicular implants,
- ✓ no inter spinal-wedge (with possible migration risks)
- ✓ respect of the inter-spinal ligament,
- ✓ semi-constraint system: the ligament placed on the basis of the spinous process restricts the flexion,
- ✓ restricts the extension in the inter-spinal space
- ✓ progressive braking in speedy movements
- ✓ fibers of knitted polyethylene composing the LVR ligament resist to about 4300 Newton.
- ✓ excellent biological acceptance,
- ✓ fibroblastic rehabilitation.

# LIMITING THE ROTATIONS

Crossing the ligament like an X puts either part in tension to any rotation sollicitation, according to a force line perpendicular to the rotation direction and thus with a maximum efficiency. ■

The 2 vertebras locking permits progressive elastic braking, right from the first degrees of mobility, making disappear the abnormal mobility as well as possibility of decoaptation accidents.

Ligament not under tension in **neutral position**  
not increase either the discal constraint or the  
posterior joint constraint in the relaxed position.

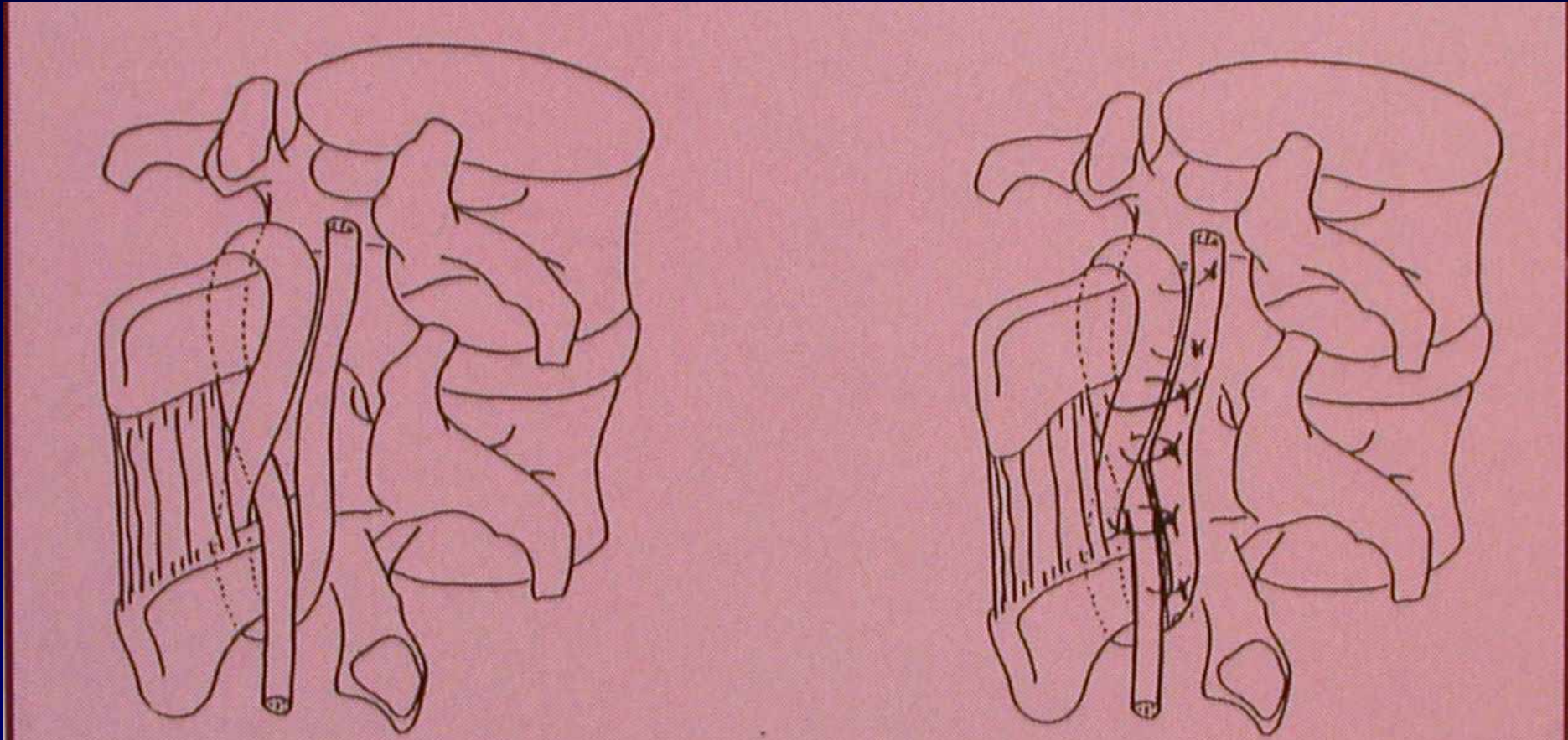


# TECHNIQUE

## PLACING THE PATIENT

The suture must be done when the rachis is in rectitude and the thorax of the patient heightened.

The patient is placed in the genupectoral position with the back side of his thighs on a horizontal bar. This position must leave the abdomen totally free to prevent any compression that could lead to operative bleedings.



## **Surgical approach**

- median posterior
- vertebral level Xray control by C-arm.
- on the side of a possible radiculagia or otherwise on the right side.
- The para-vertebral grooves are partially exposed, but the spine apophysis and the inter-spinal ligaments are strictly respected.
- On the other hand, at the sacrum level, the dissection has to be extended down enough and laterally permits fixing on the sacrum, between the S1 and the S2 by staples

## **FIXING THE LIGAMENT ON L3-L4 or L4-L5**

The ligament is introduced with a dissector under the basis of the inferior spine process, then through inter-spinal ligament, then above the superior spine process without bone excision (weakening effect)


The lumbar spine, initially kyphosed to free the inter-spinal space is then placed right and both extremities of the ligament are sutured one next to the other with a non resorbable thread.

3 traction threads are then passed a forth between both crossed parts of the ligament, tending it slightly and fixing it firmly into the inter-spinal space.


An absorption wedge is thus obtained between the two spinous process. Some precautions are necessary:

The ligament must be introduced as deep as possible, just at the basis of the spines.

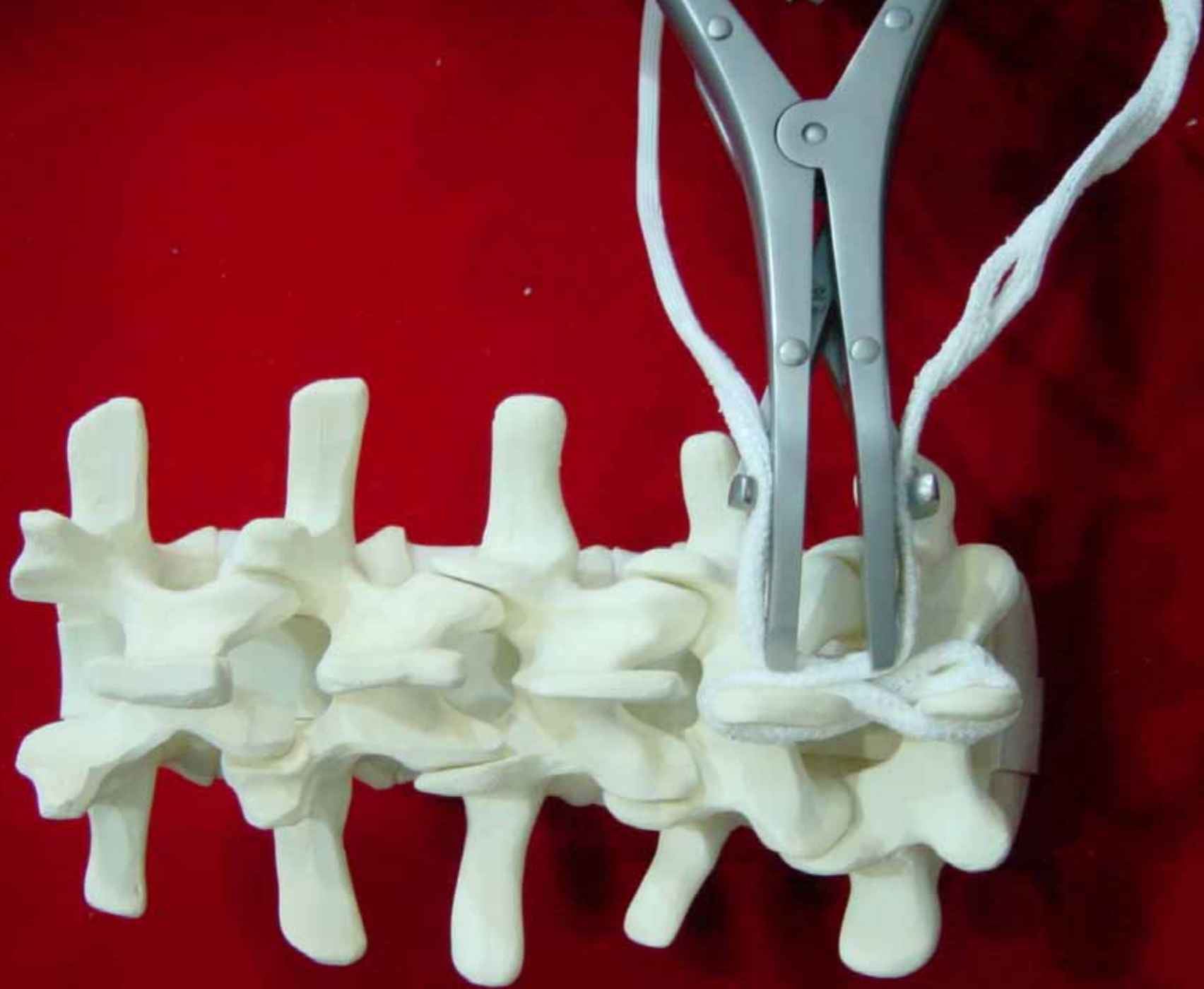
The suture under tension of the ligament during the operation must show a normal anterior opening of the disc on the lateral C-arm picture

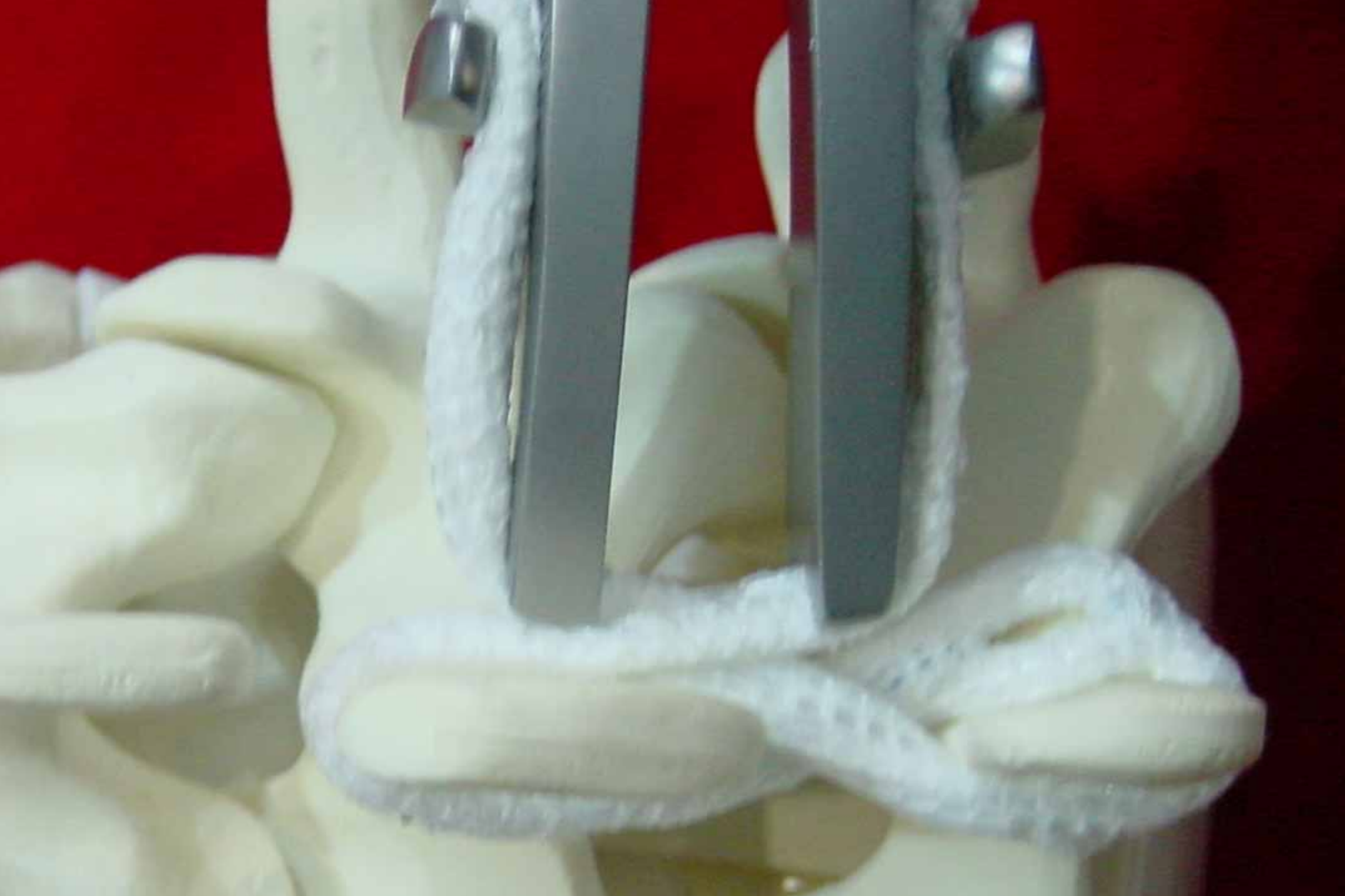

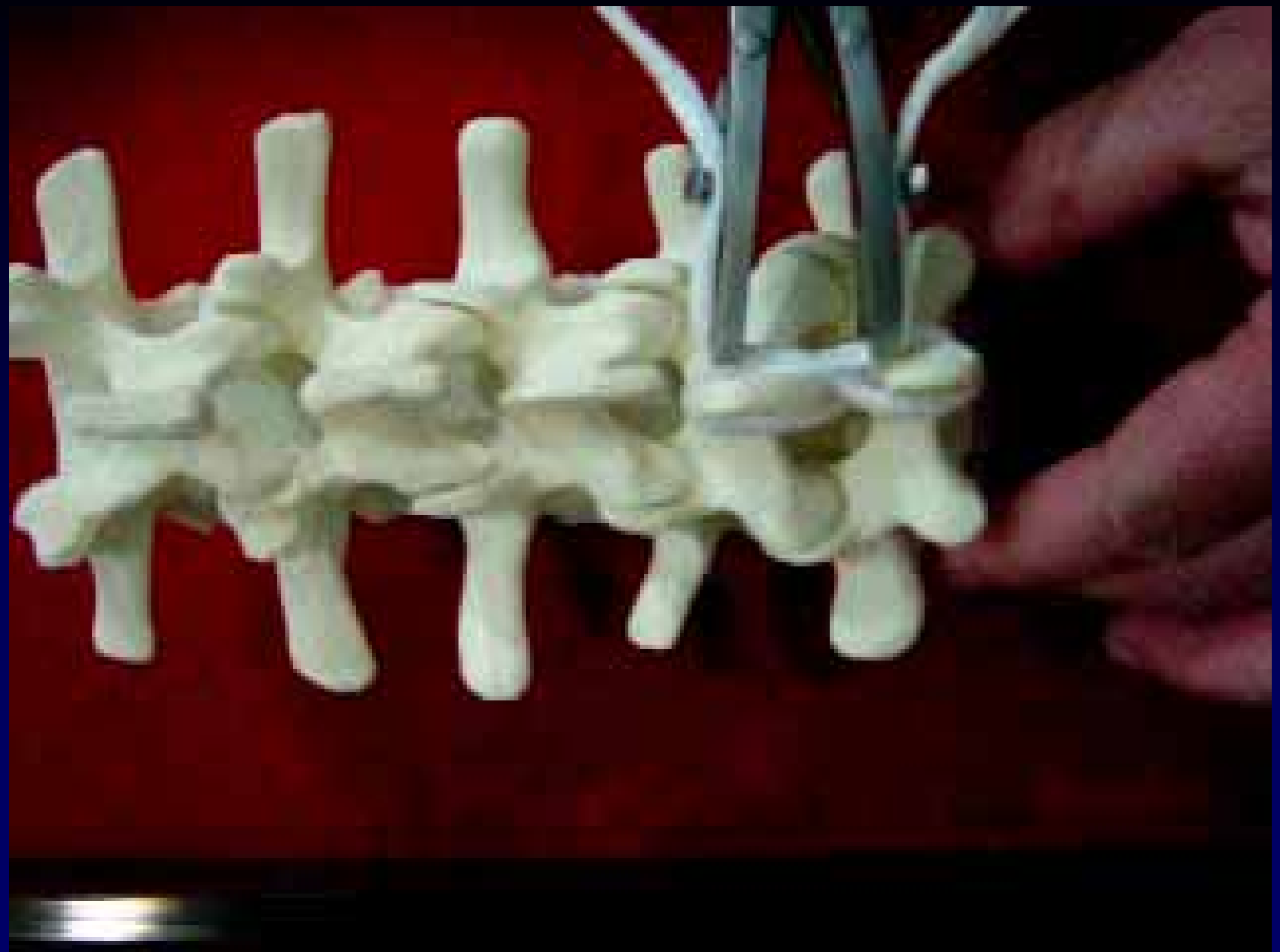



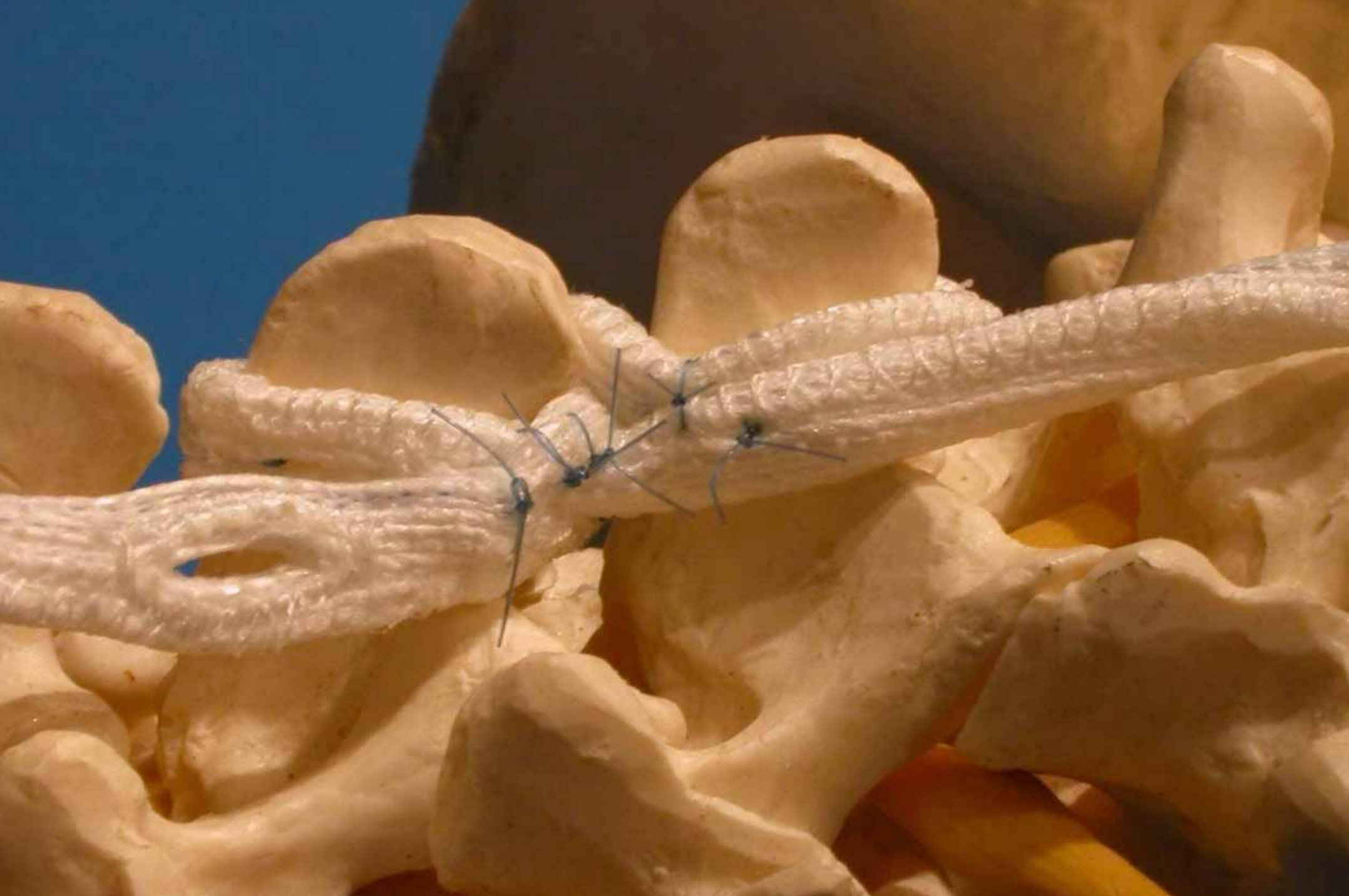


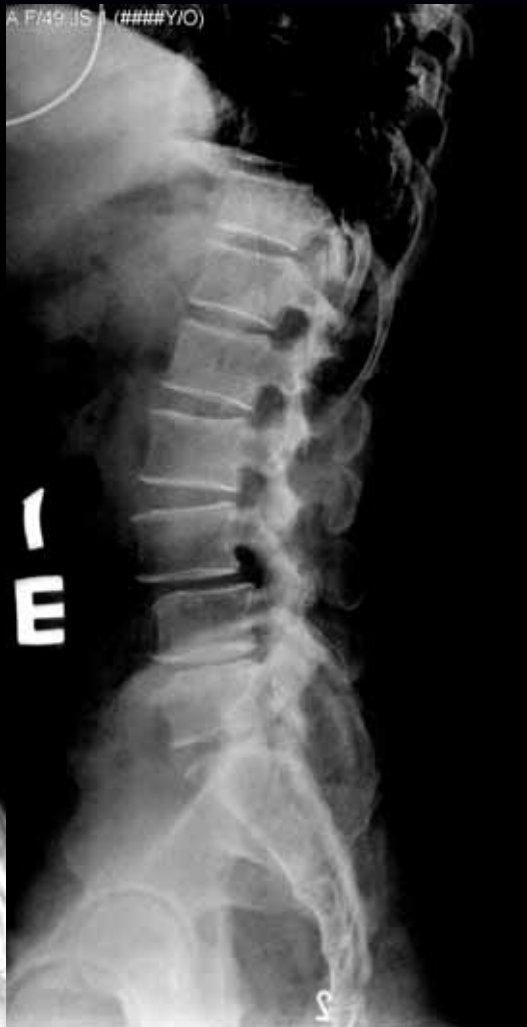
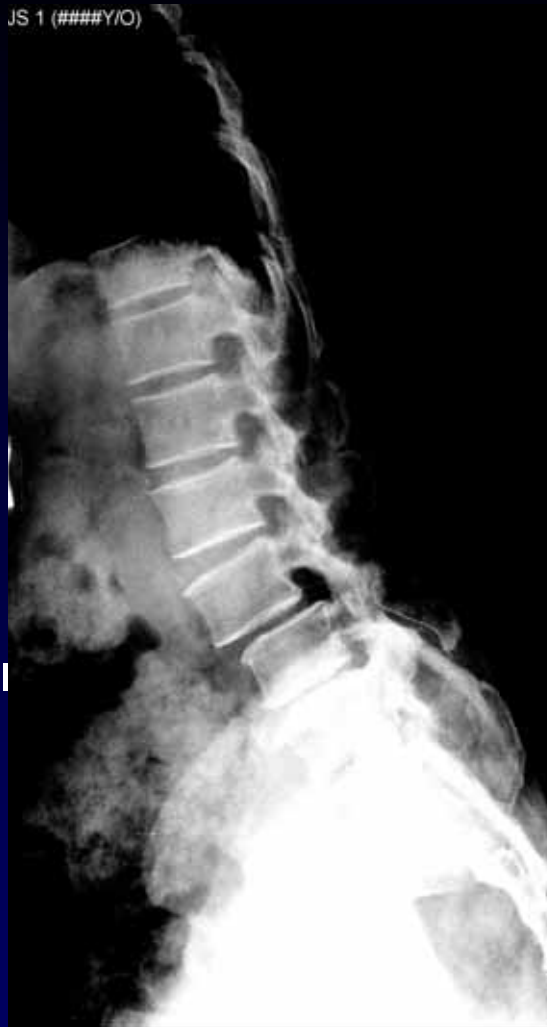
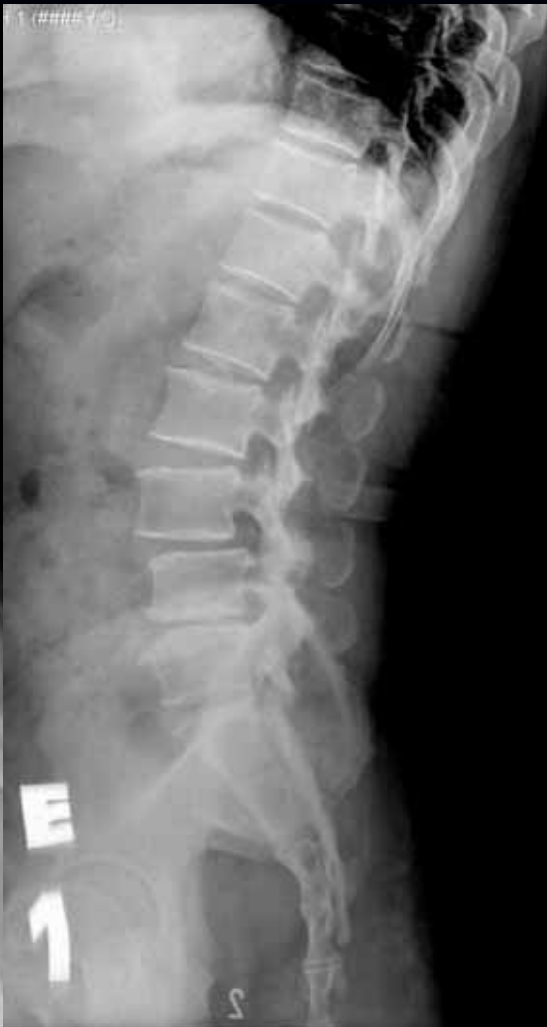
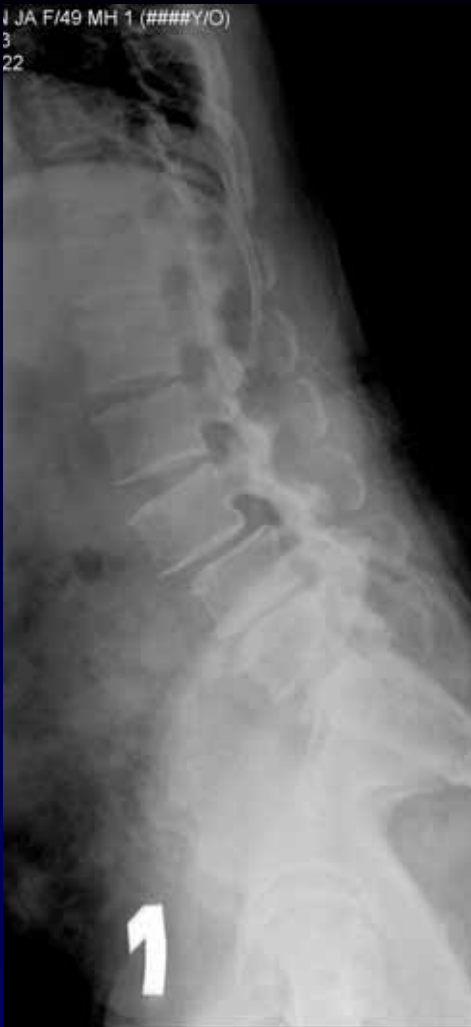
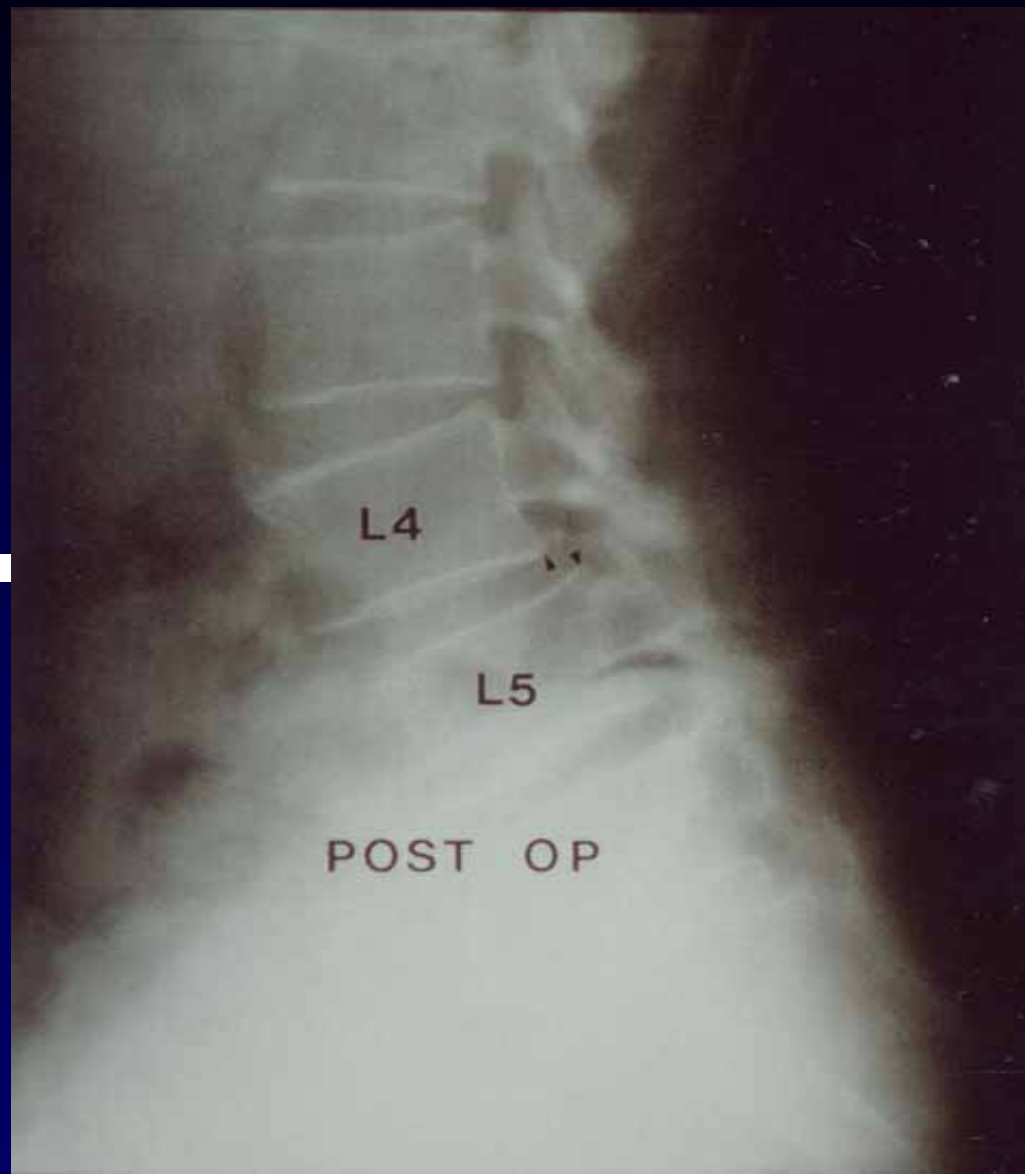






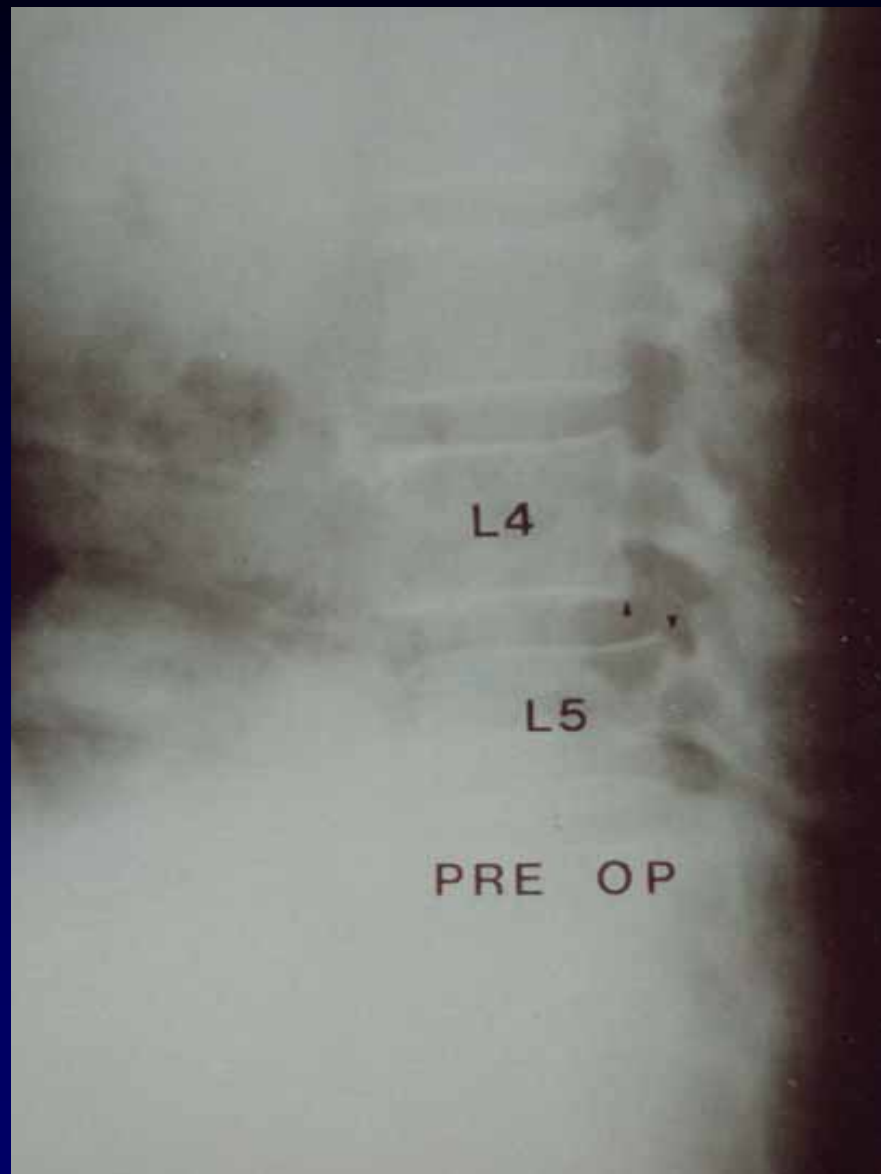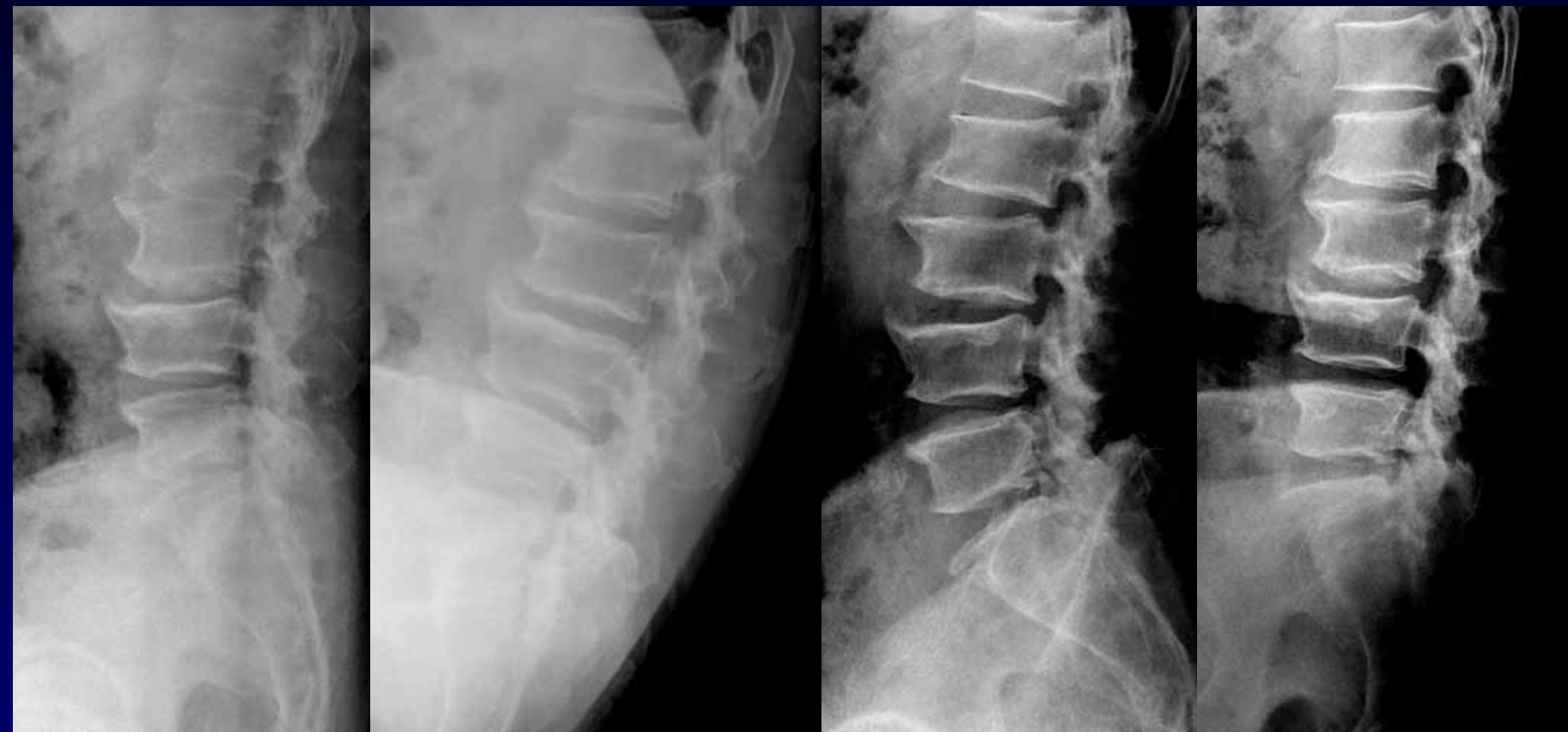L3L4

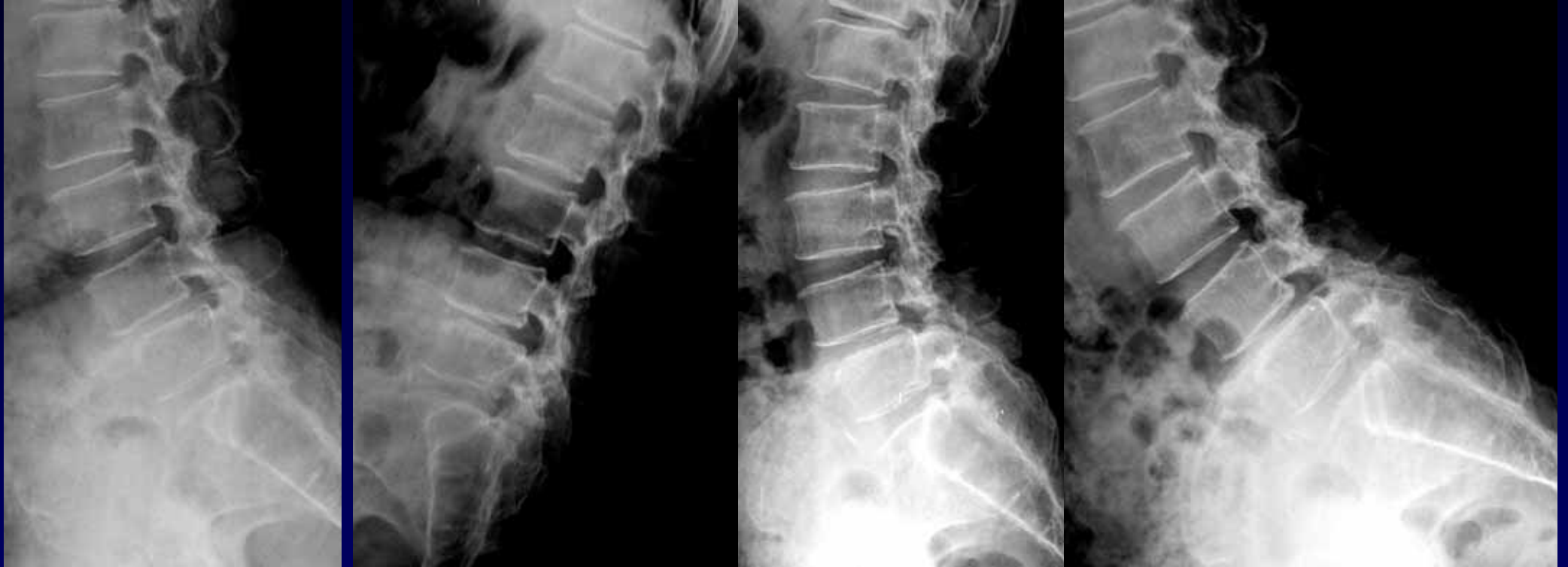..., 10051923, op : 01.6.1

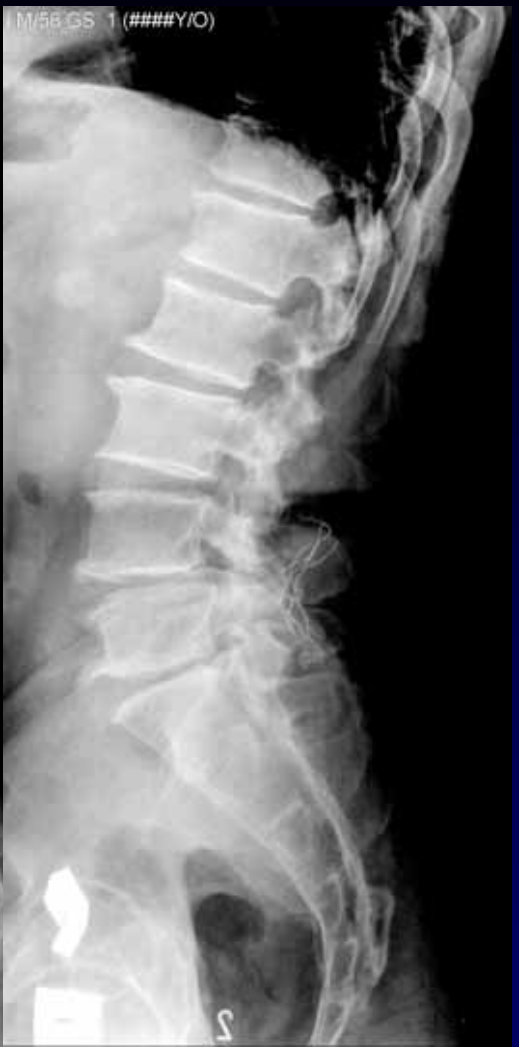
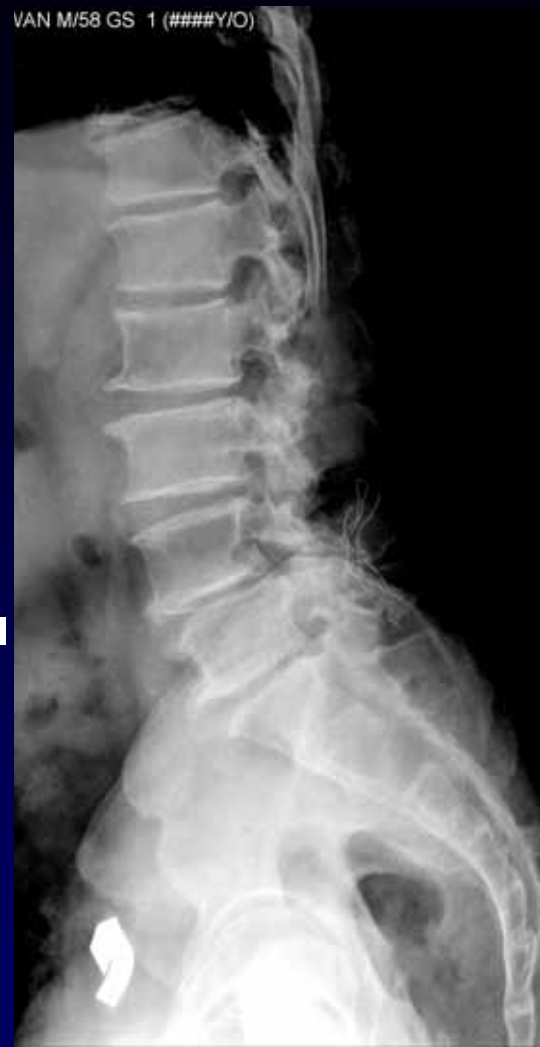
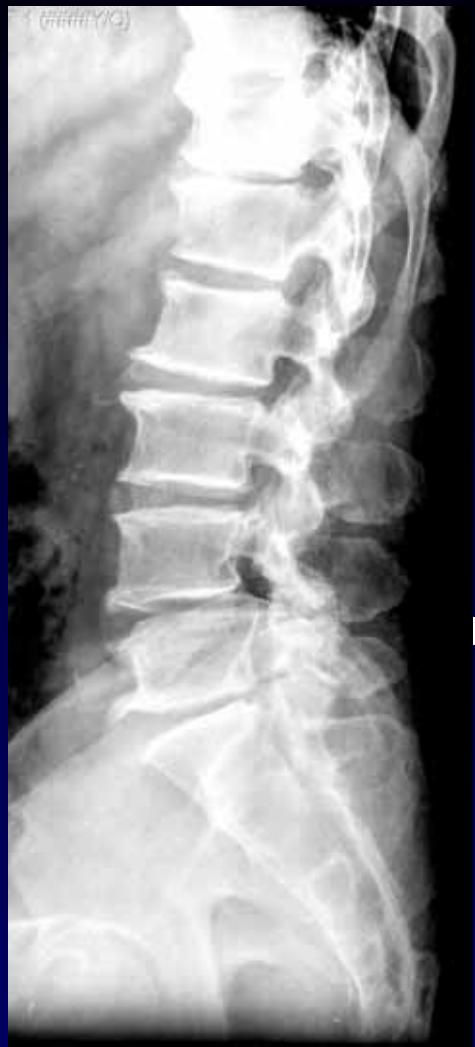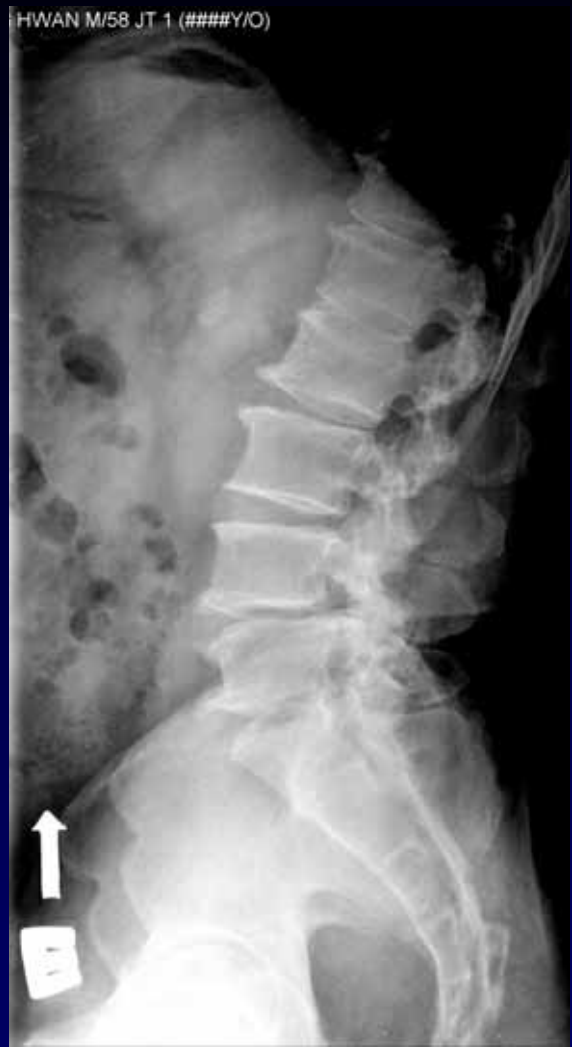... 10010029, 67/M, 2001-2-7

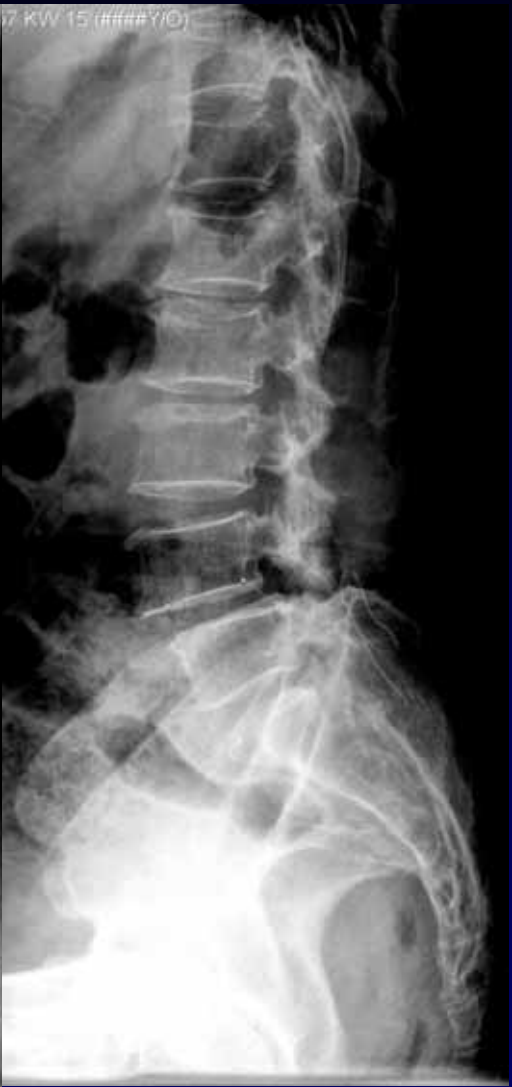
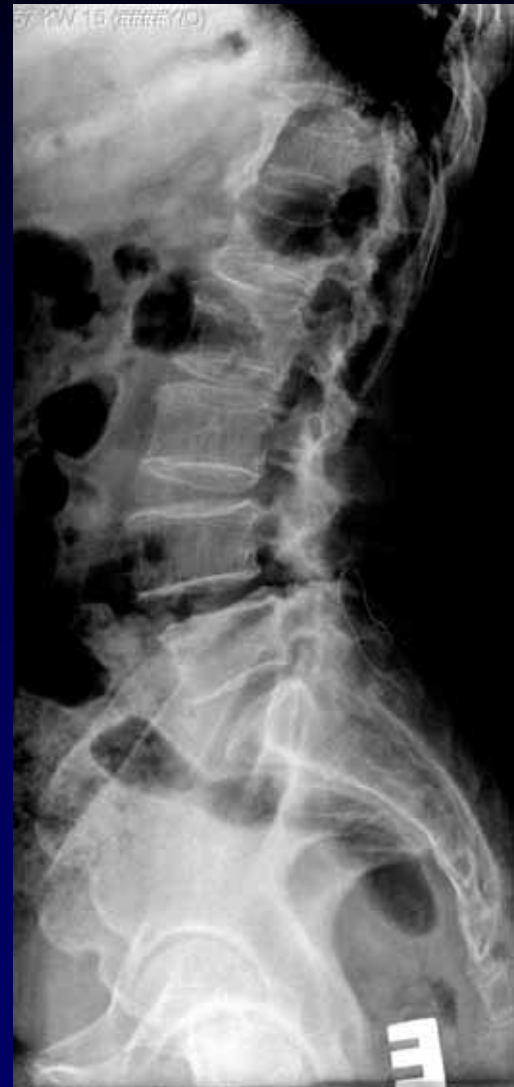
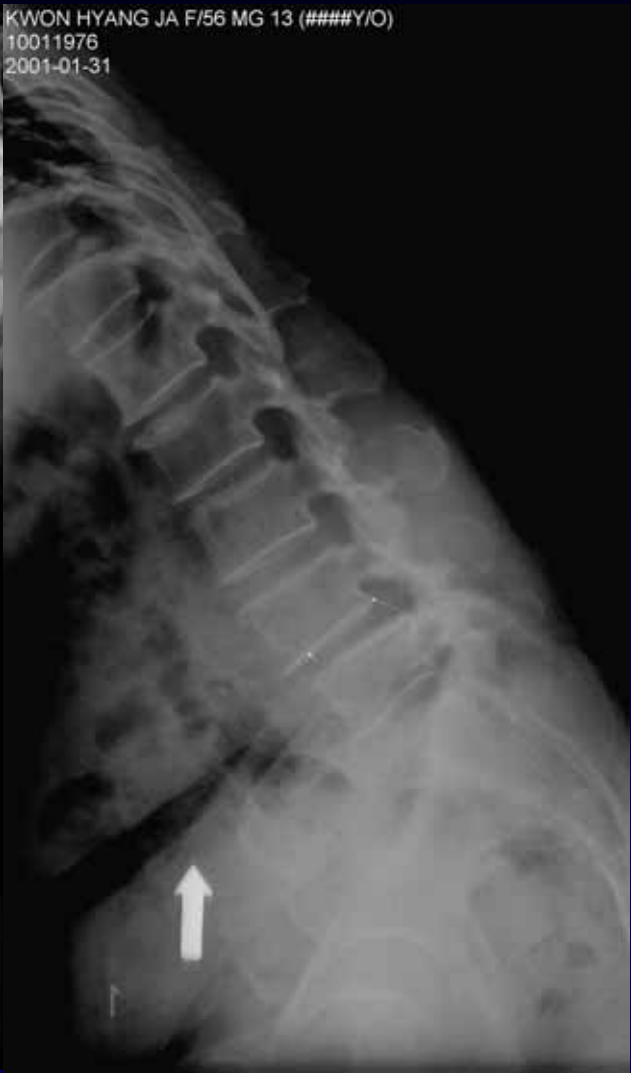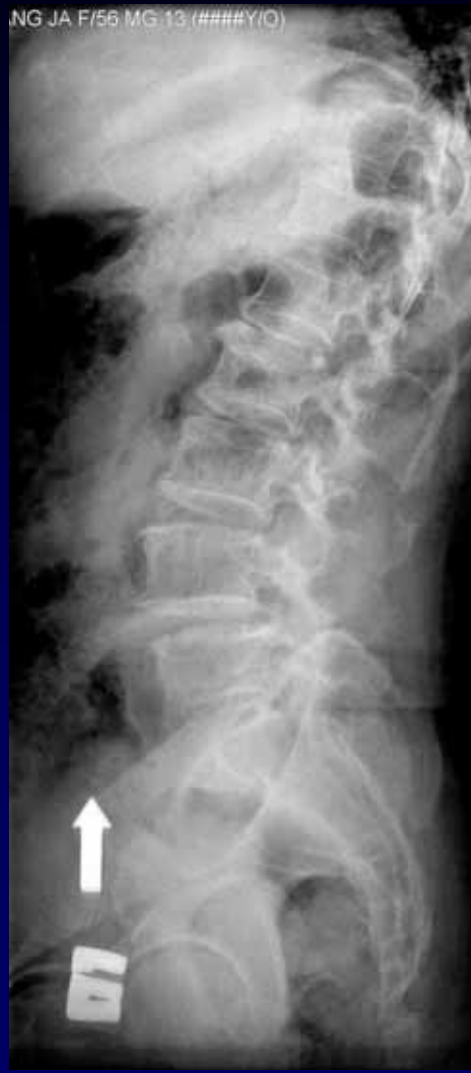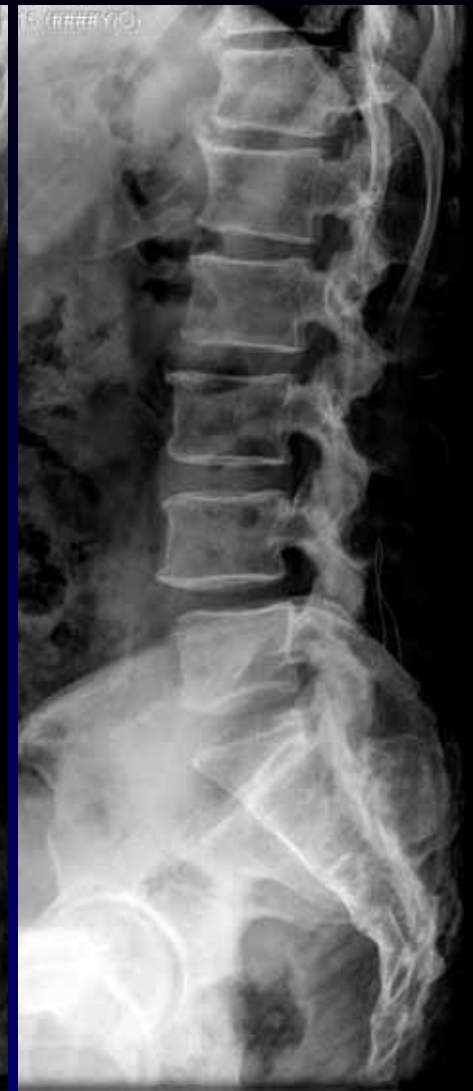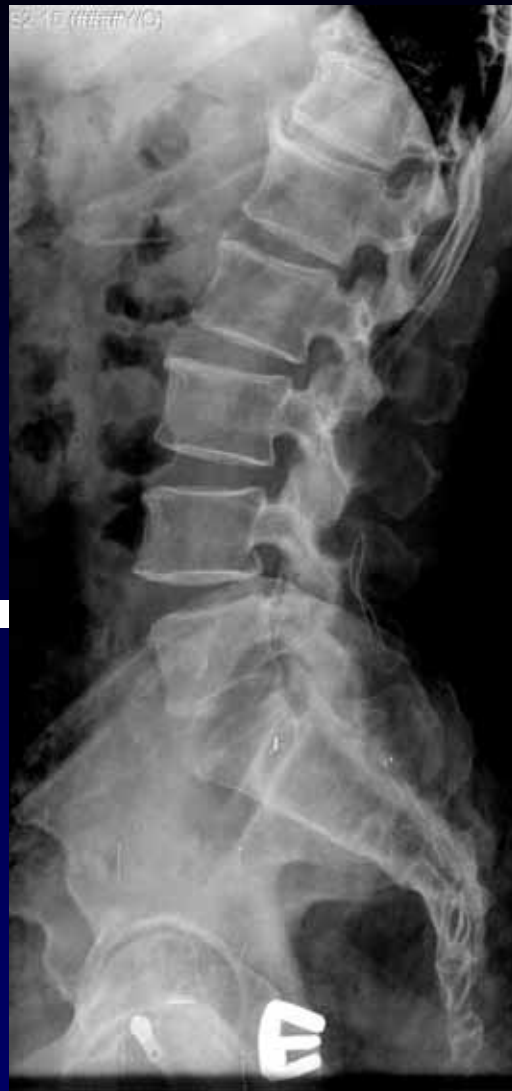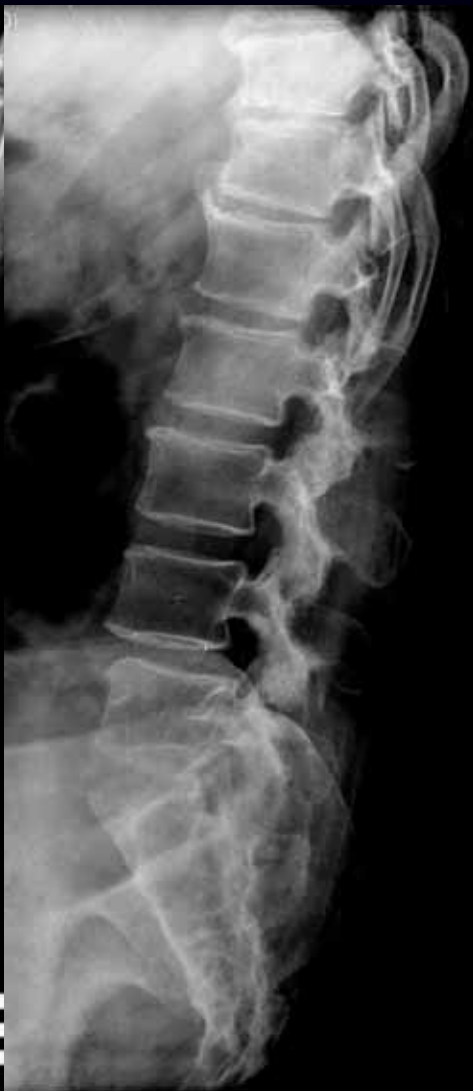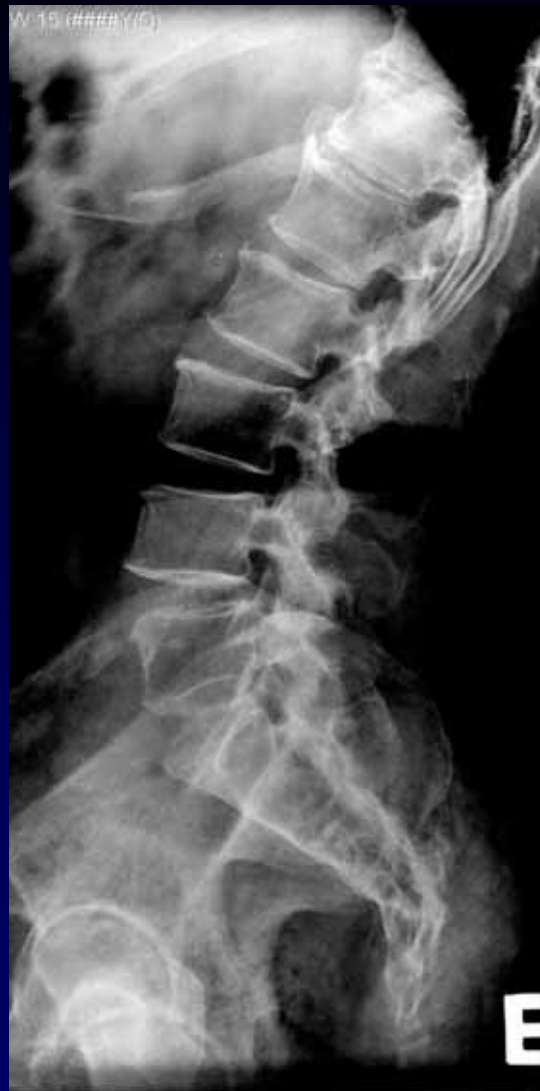... 10020906, 66/F, 2001-3-16

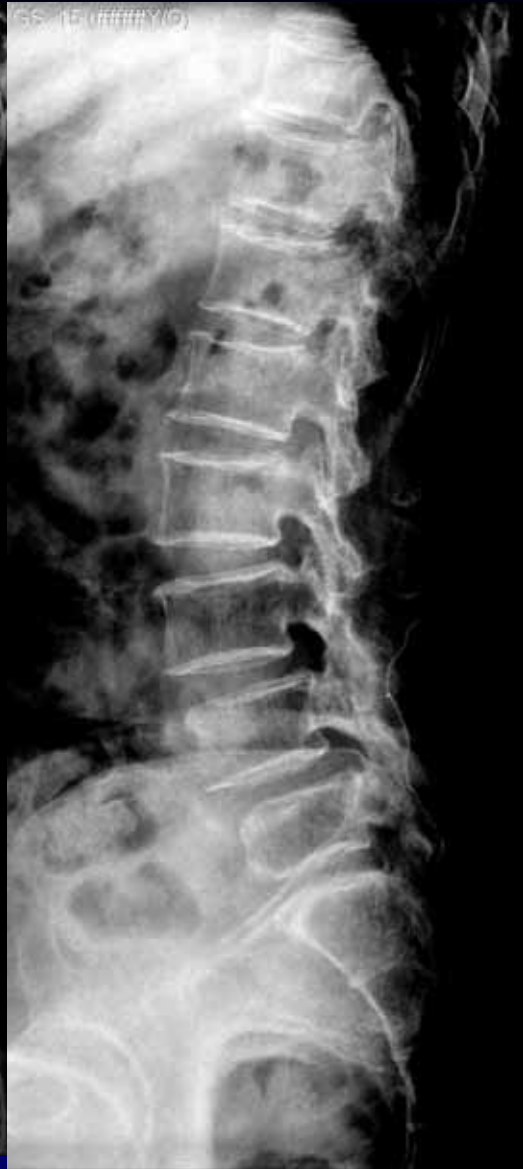
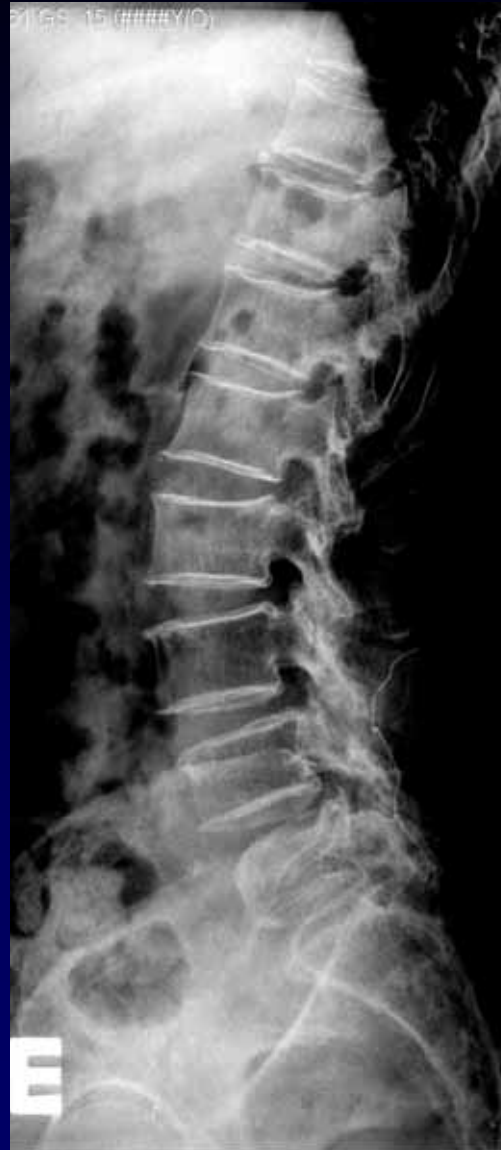
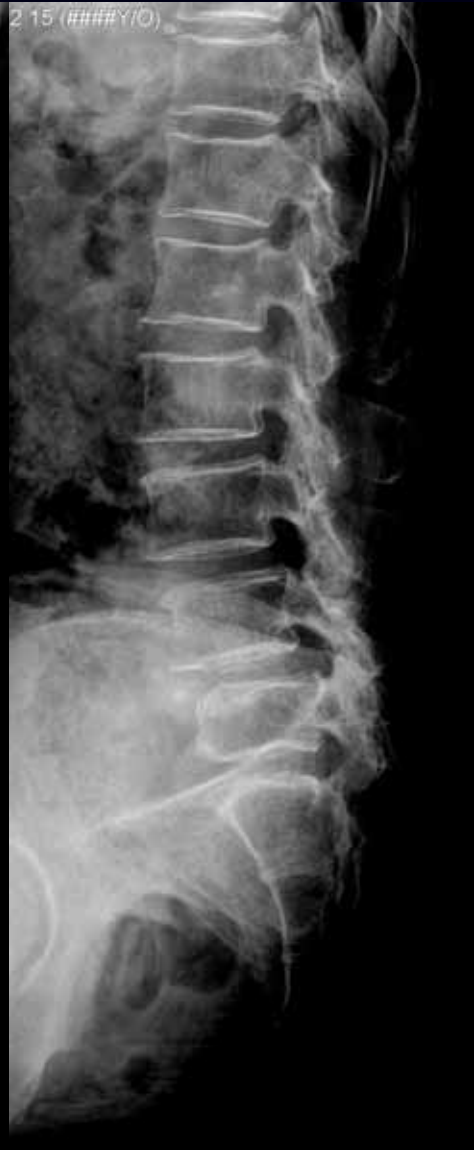
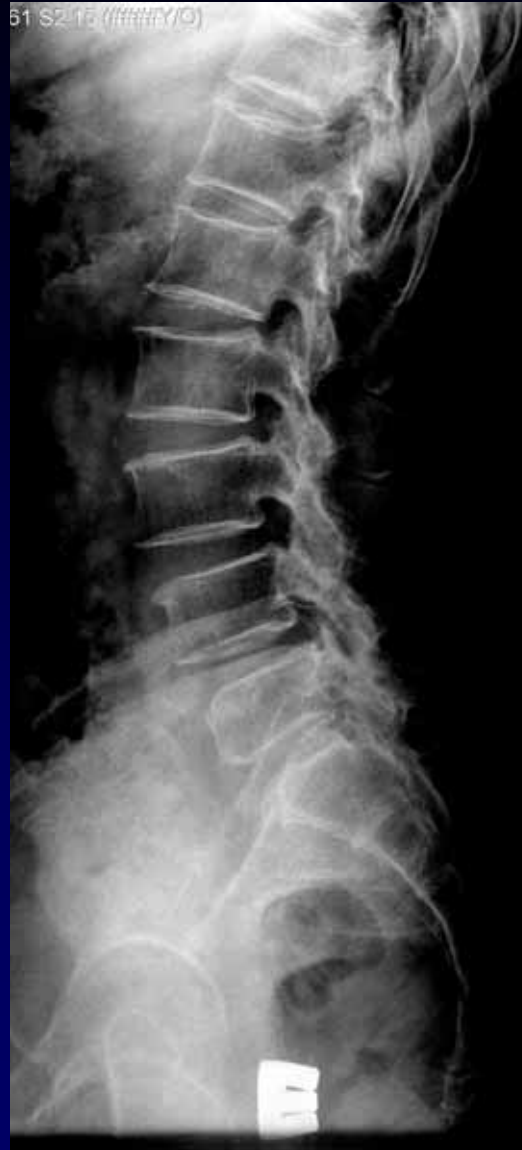
..., 10030899, op : 01.4.6







## **L5-S1 LIGAMENTOPLASTY**

The L5-S1 stabilization requires ligament fixing on the sacrum with 2 indented staples,

The ligament is passed as explained before, above the L5 spine, crossed into the L5-S1 space and fixed to the sacrum under the protusion emergence of the S1 root, at the S1-S2 pedicle level, about 4 cm from the median line.

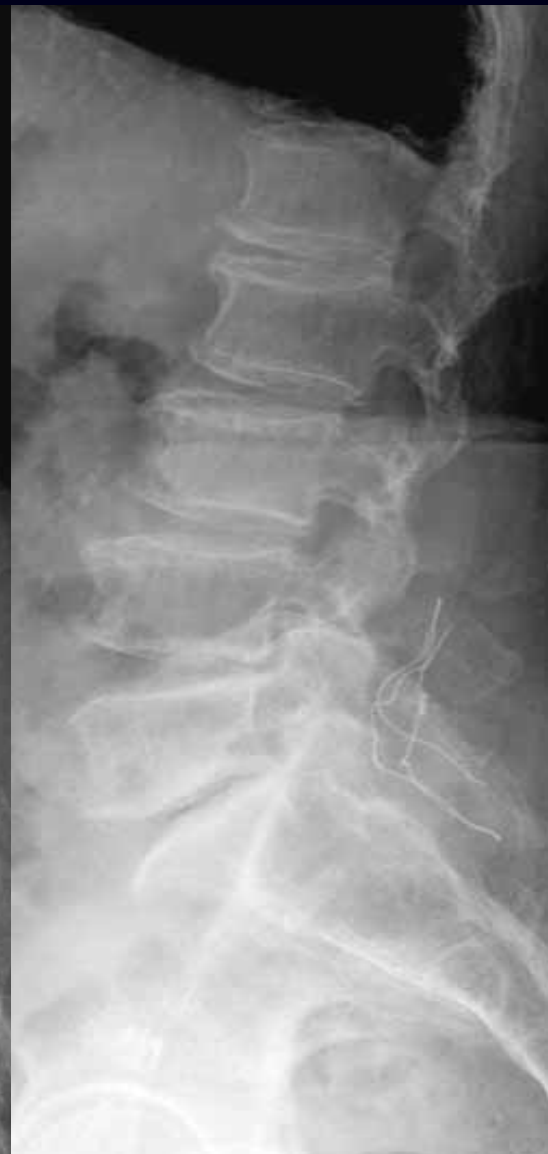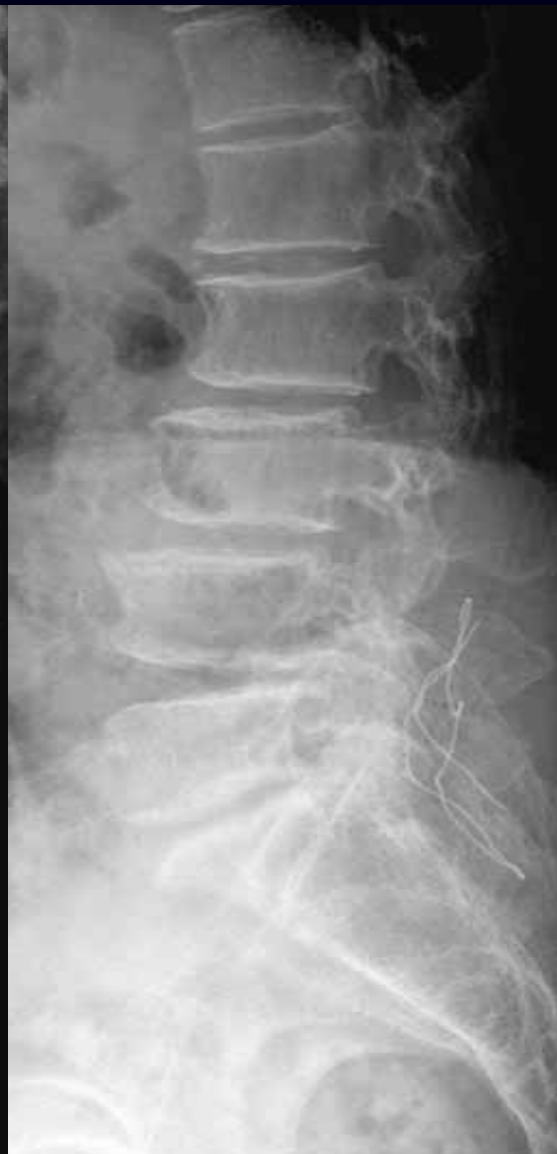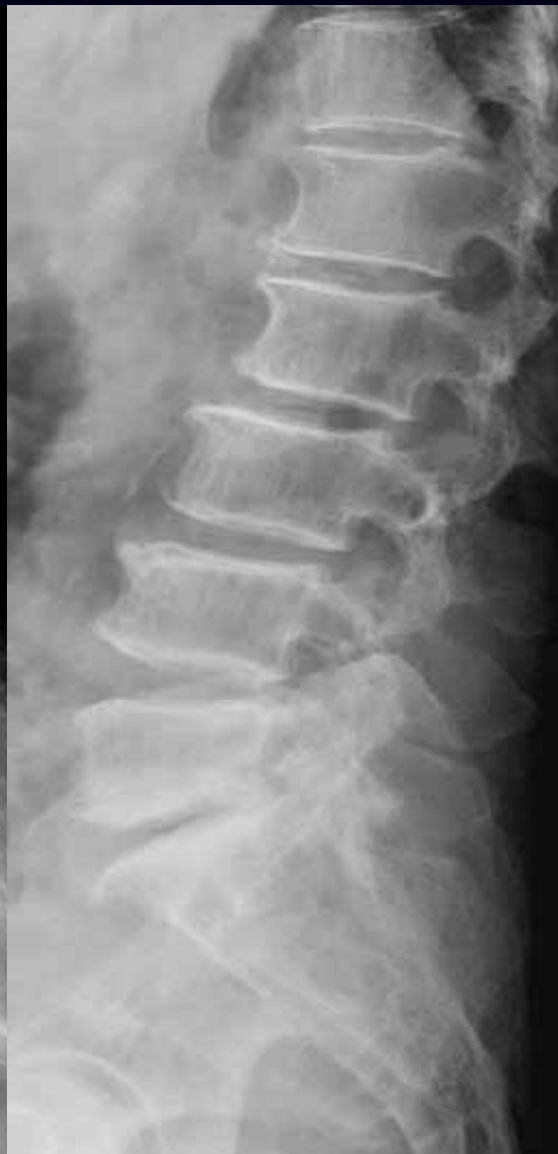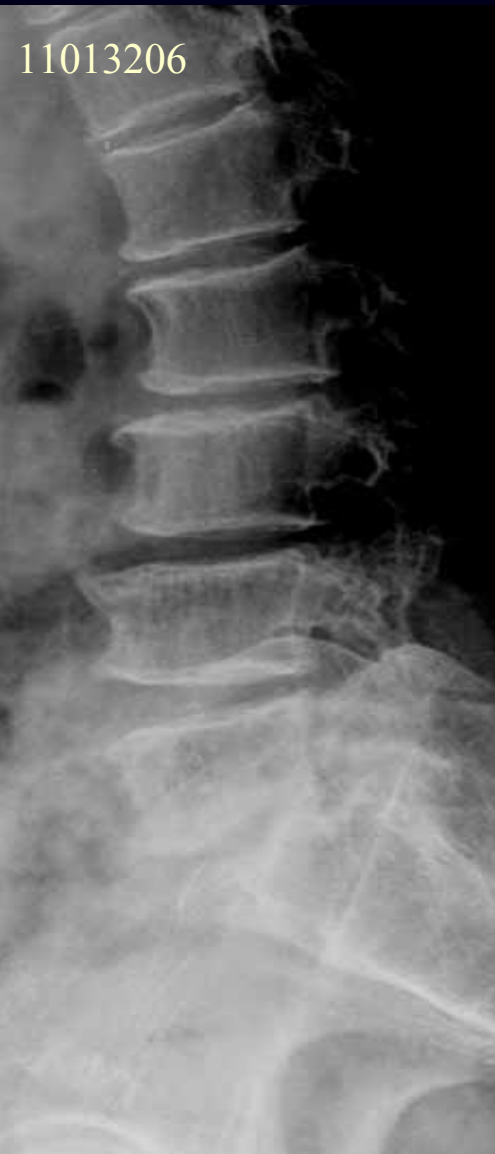The staples insure a secure fixing of the ligament.

## **DOUBLE L4-L5 and L5-S1 LIGAMENTOPLASTY**

In case of an important instability at 2 levels, the same ligament can be used in L4-L5 and L5-S1 and fixed to the sacrum.



LSH(F/64)



Preop

Postop

# **COMBINATION OF A DISCAL EXCISION AND A RADICULAR NEUROLYSIS**

In case of crural compression or of clear sciatica, revealed by the pre-operative images and expressed by persisting radicular pains, the opening of the vertebral canal is necessary. Vertebral stabilization lowers then any risk of the post operative fibrosis.

## **POST OPERATIVE CARE**

Drainage with a Redon plastic tube is carried out after 48 hours.

A plastic corset is optional



# INDICATIONS

The inter-vertebral ligamentoplasty is indicated in painful inter-vertebral instabilities with or without radicular irradiation.

This technique is an alternative to lumbar arthrodesis without sharing its disadvantages (complete blocking, irreversible character, possible fusion difficulties), and getting the same results on lumbar pains.

Finally, the vertebral stabilization diminishes the risk of reactional fibrosis: frequent after a classical discal excision with persisting abnormal mobility. It can even be a treatment for a peri-radicular fibrosis, combined or not with neurolysis.



## RESULTS

The results are appreciated according to usual criteria:

3 years experience

Excellent:48%

Good:31%

Fair :12%

Poor: 9%



The results are the same for any operated level.

.

## DISCUSSING THE RESULTS

The 79% of very good and good results incite us to follow up this technique.

The unsatisfactory results seem to be due to:

too far extended lumbar degeneration

excessive per-operative tension of the ligament,

increasing the rear joint constraints.

# CONCLUSION

- A soft stabilization with inter-spinal ligamentoplasty seems to give a high percentage of good and very good results on some often very damaged rachis.
- The reversible character of this surgery incites to suggest it instead of lumbar arthrodesis.
- A longer following of the patients will however be necessary in order to be sure of the final stabilization.